

Managing the appendicular stump during a laparoscopic appendectomy

L. I. Partecke¹, S. Dietrich²

¹ *Universitätsmedizin Greifswald, Surgical Clinic, Department of General, Visceral, Thoracic, and Vascular Surgery, Ferdinand Sauerbruch Straße, 17475 Greifswald partecke@uni-greifswald.de (Corresponding author) and*

² *Universitätsmedizin Greifswald, Surgical Clinic, stephan.diedrich@uni-greifswald.de*

Keywords:

Appendectomy, appendicitis, appendicular stump, appendix operation, laparoscopy, endostapler, endoloop, clip

The appendectomy continues to be the most common emergency operation in general and visceral surgery. The conservative antibiotic treatment touted by some working groups in recent years does not represent a serious alternative to surgical intervention. Even though studies have shown that cases of uncomplicated appendicitis do not necessarily require surgery in the middle of the night, and that delaying the operation slightly does not increase morbidity, all surgical clinics must have trained physicians on staff who can provide high-quality surgical therapy for acute appendicitis at any time of the day or night.

This is why continuing education for surgeons in appendectomy techniques is so highly valued. In 1894, McBurney pioneered McBurney's incision on the right side of the lower abdomen. This form of open surgical incision shaped the operative techniques of generations of surgeons. It was performed safely in a highly standardized way. In the early 1980s, Kurt Semm, a gynecologist from Kiel, Germany, performed the first laparoscopic appendectomy (LA). Semm was already aware that the crucial component of LA was the safe management of the appendicular stump.

Only when this is successful can LA compete with the open procedure and its advantages be realized. Similar to the open procedure, Semm closed the base of the appendix with a Roeder loop followed by a purse-string suture and Z-suture in his first description of his laparoscopic technique. This procedure constituted the standard approach to LA in many clinics for a number of years.

The main factors behind the slow adoption of LA as a standard procedure were primarily intra-abdominal abscesses that were frequently described in early years, as well as significantly higher

costs compared to the open procedure. In addition, LA had to compete with the high degree of standardization and low rates of complication associated with the open appendectomy technique. Moreover, the laparoscopic technique that Semm described was very challenging for surgeons who had less experience with laparoscopy.

With the introduction of linear staplers in laparoscopic surgery and more and more surgeons with better and better training in laparoscopic surgical techniques, LA gained broader acceptance in Germany as well and can now be considered the standard approach even in cases of advanced appendicitis.

As mentioned above, the decisive step in LA is the safe closure of the base of the appendix. The most commonly used techniques that are used to provide safe, easy, highly-standardized care that is as cost-effective as possible are:

- the endoloop (made of PDS® or Vicryl®),
- the clip (non-absorbable polymer clip or titanium clip),
- and the endostapler.

The endostapler

The main advantage of the endostapler is that it is fast and easy to use, thanks to its ability to seal and transect tissue in a single step. It also offers the possibility of tangentially resectioning the wall of the cecum. It is simple to use on an appendix with minimal inflammatory alterations. However, managing the base of the appendix in cases of advanced appendicitis requires extensive experience. The main disadvantage of the endostapler is its high price. Therefore it should only be used if the infection extends to the base of the appendix or if the base of the appendix has thickened considerably.

Thus there is a clear indication for the use of the endostapler: advanced appendicitis that extends to the base of the appendix.

The endoloop

Semm used endoloops (Roeder loops) during his earliest applications of LA. They are either made of Vicryl® or PDS® and are used primarily in cases of uncomplicated appendicitis. The correct placement of the loop requires laparoscopic skill, meaning there is a certain learning curve involved. The technique itself is simple: the appendix can be resected between an endoloop placed near the base and one placed more distally. The loop is also a good option in cases of a thicker appendix base.

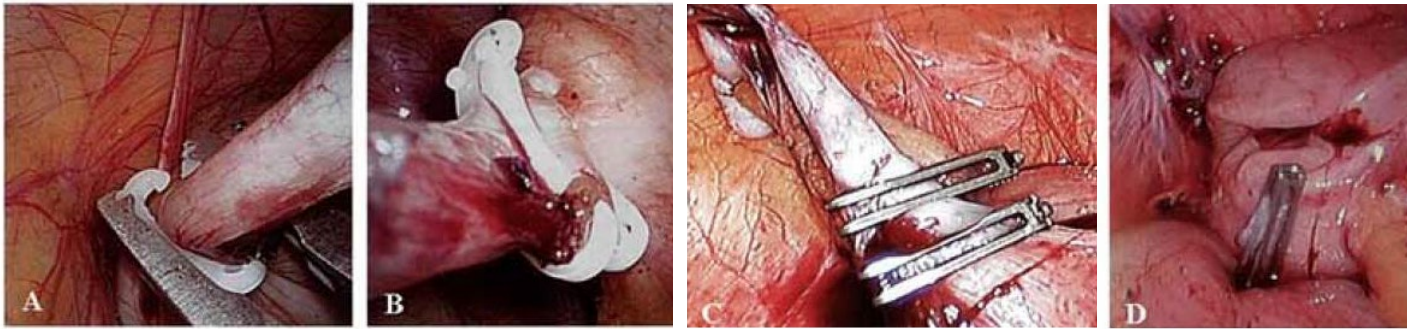


Fig. 1:
A: Hem-o-lok clip: Application of the clip at the base of the appendix. The distal closing mechanism can easily be seen;
B: Hem-o-lok clip: Situation following management with both a distal and proximal clip prior to resecting the appendix between the two clips;
C: Titanium DS-Clip: Two clips have been applied - situation prior to resecting with scissors. The distal closure can easily be seen here as well;
D: Titanium DS clip: Situation following the removal of the appendix - one clip at the appendix base ensures safe closure.

The sinking of the appendix stump was always a frequent topic of discussion. In the early years of LA, sinking the appendix stump was desired. In the meantime, several prospective studies have shown that it is safe to manage the stump using a single, unsunk-en PDS® or Vicryl® loop. Managing the stump with two loops is not safer; but instead increases the risk of developing gangrene on the stump.

The cost of endoloops is comparatively low. In addition, surgeons can make their own knots for distal management, thereby reducing costs further.

The clip

To date, two different clip systems have been used in LAs: The polymer Hem-o-lok clip (Hem-o-lok MLX polymeric clip, Weck Closure Systems, USA) and the titanium clip (DS-Clip, Aesculap, Germany). Both clips have a closing mechanism on the distal ends and therefore remain securely in place following application (Figure 1 A-D).

They are significantly easier to use than endoloops, particularly when it comes to placing them correctly on the base of the appendix. It is easy for young surgeons to learn how to use them. Their use resembles the management of the cystic duct during a laparoscopic cholecystectomy, for example.

The disadvantage of clips is that they can only ensure safe closure for a limited range of appendix diameters. This is approximately 16 mm for the Hem-o-lok clip and approximately 20 mm for the DS-Clip. For both clips, placing only one clip at the base is sufficiently safe. In a study designed to evaluate use of the titanium DS-Clip during an LA, Rickert et al.* asked the practicing surgeons how they would assess the fit of the clip, handling during application, and visibility during application. In all categories, the DS-Clip was predominantly rated "excellent" or "good". 41 percent of the basic assessments rated the clip as "excellent" and another 41 percent rated it as "good". Only 2 percent of the assessments rated it as "average." The study is obviously somewhat biased. However, it does show that the clips are very easy to use during a laparoscopic appendectomy. The price for five Hem-o-lok clips is about € 19 and about € 80 for four titanium DS-Clips, meaning that we can assume that clips will be used to manage the appendix base in the future, at least in cases of uncomplicated appendicitis. At the moment, the Hem-o-lok clip is significantly less expensive, whereas the titanium DS clip can manage a broader appendix base.

Neither system offers a true advantage over the other, however, meaning that the choice of system will depend on the personal preferences of the individual surgeon or surgical clinic.

* Rickert A, Bönninghoff R, Post S, Walz M, Runkel N, Kienle P. Appendix stump closure with titanium clips in laparoscopic appendectomy. *Langenbecks Arch Surg.* 2012 Feb;397(2):327-31

Tab. 1: Comparison of the advantages and disadvantages of the three techniques of appendix base closure in laparoscopic appendectomies (adapted from and used with permission from the Georg Thieme Verlag)

Procedure	Advantages	Disadvantages
Endoloop	<ul style="list-style-type: none"> can be used in most cases safe in cases of mild inflammation use does not depend on the diameter of the appendix cost-effective 	<ul style="list-style-type: none"> high level of training required exposed mucosa on the appendix stump longer appendix stump primary management of the appendix base with subsequent retrograde dissection of the mesoappendix is not possible
Clip	<ul style="list-style-type: none"> easy to use minimal mucosa remaining on the appendicular stump primary closure and removal of the appendicular base and subsequent retrograde mobilization of the appendix possible cost-effective more clips can be used to manage the mesoappendix and the appendicular artery 	<ul style="list-style-type: none"> the diameter of the appendix base is limited to 16-20 mm may not provide enough safety if the appendix base is inflamed. non-absorbable
Stapler	<ul style="list-style-type: none"> safer closure of the appendix base, even when the appendix base is inflamed possibility of partial cecum wall resection no mucosa remaining on the appendicular stump easy to use stapler can be closed and appendix can be resected in a single step primary management of the appendix base and subsequent retrograde dissection of the mesoappendix is possible 	<p>Possible malfunctions:</p> <ul style="list-style-type: none"> cutting without stapling stapling without cutting incomplete closure of the staples loss of the staples staples cannot be absorbed expensive

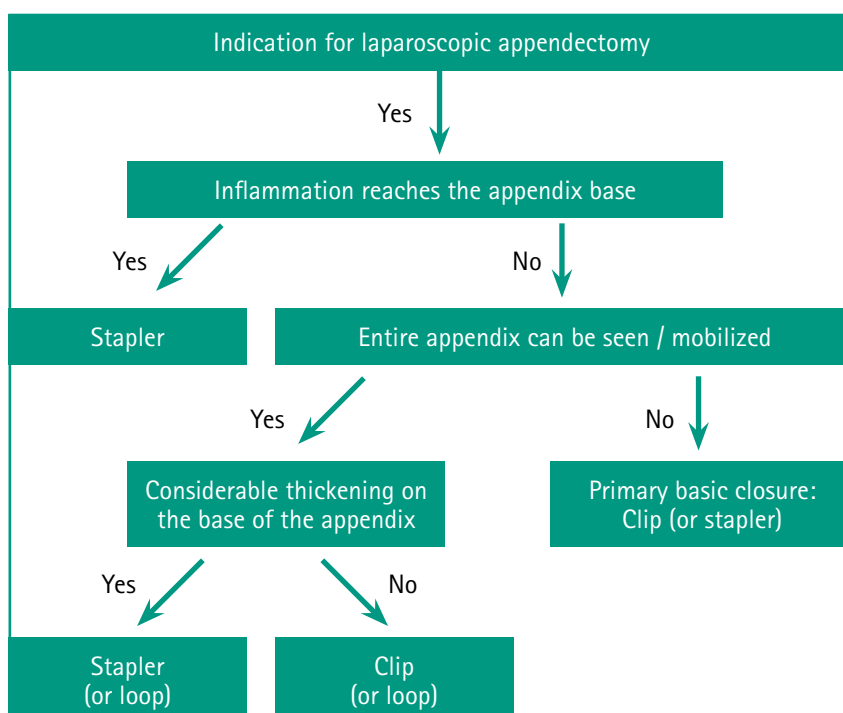



Fig. 2: Recommendation for making a considered choice of procedure to manage the appendix base as part of a laparoscopic appendectomy (adapted from, used with permission from the Georg Thieme Verlag)

Conclusion

The advantages and disadvantages of the three methods of managing the appendix base during an LA (endostapler, endoloop, and clip) are summarized in Table 1. The available data from the literature and the specific features of the three competing methods suggest the following recommendation for the standardized management of the appendix base during an LA, depending on the local infection situation (Fig. 2, adapted from:):

In the vast majority of cases of uncomplicated phlegmonous appendicitis, the appendix base can be safely managed with a single clip at the base. Each clinic should decide on one of the two clip systems in order to minimize morbidity during routine use. Due to its ease of use, the clip could become the standard approach for uncomplicated appendicitis in the future. For complicated diagnostic findings of advanced appendicitis that also includes the appendix base, the stapler is indicated.

 You can find this article at BDC|Online under the heading News | CME Articles.
Partecke L.I. /Diedrich S. Die Appendixstumpfversorgung bei der laparoskopischen Appendektomie. *Passion Chirurgie*. 2013 April; 3(04): Artikel 03_01.